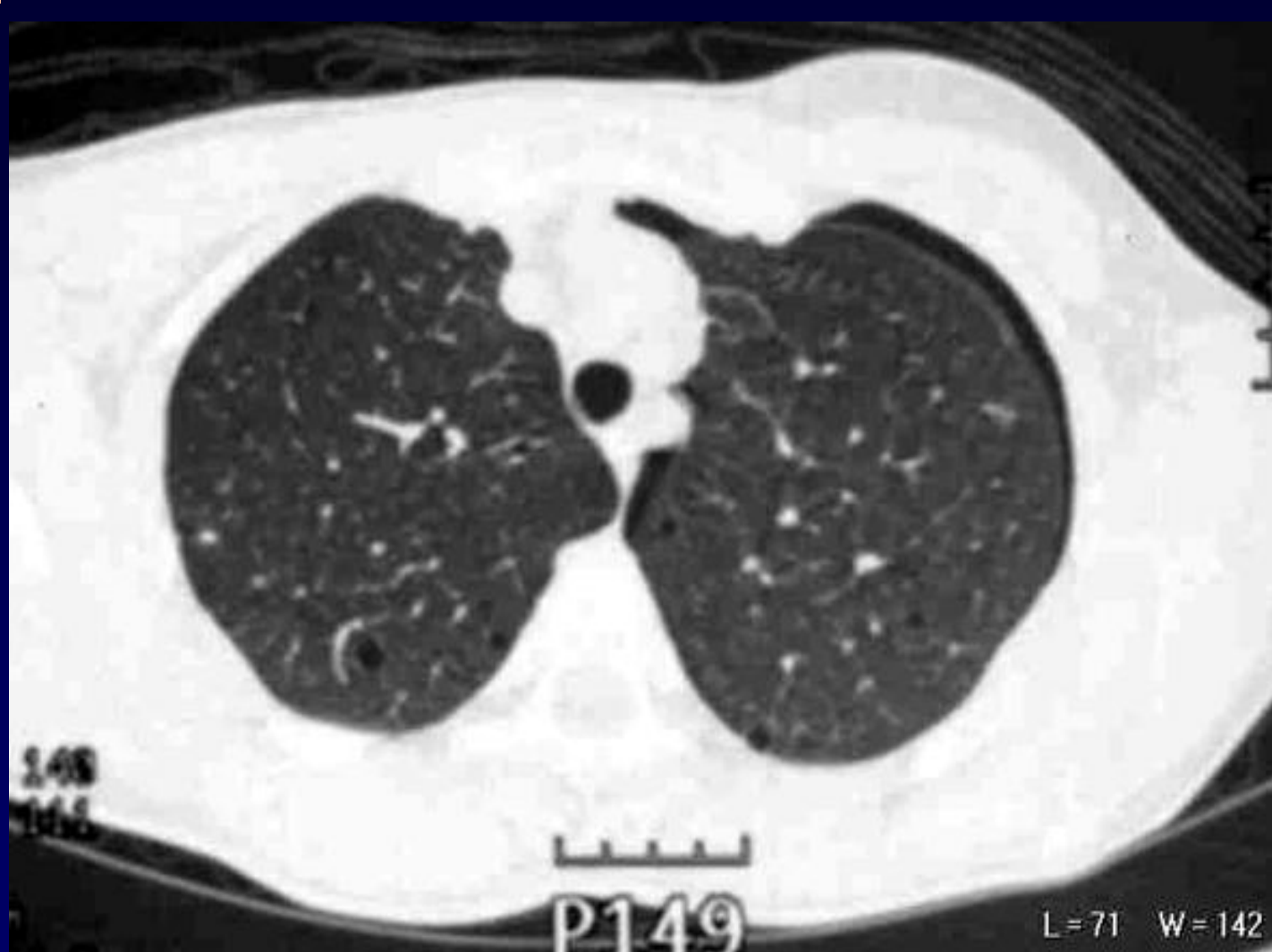


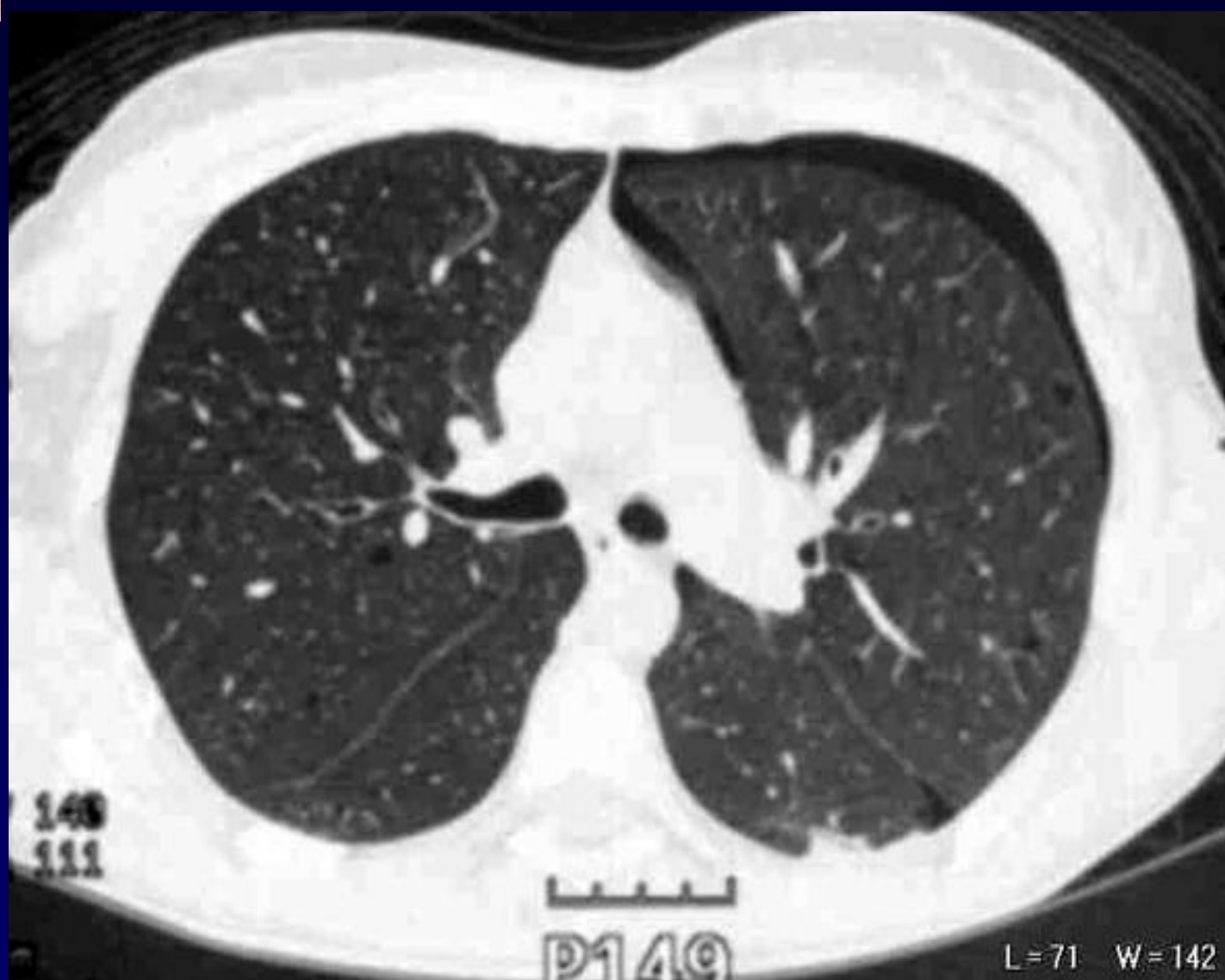


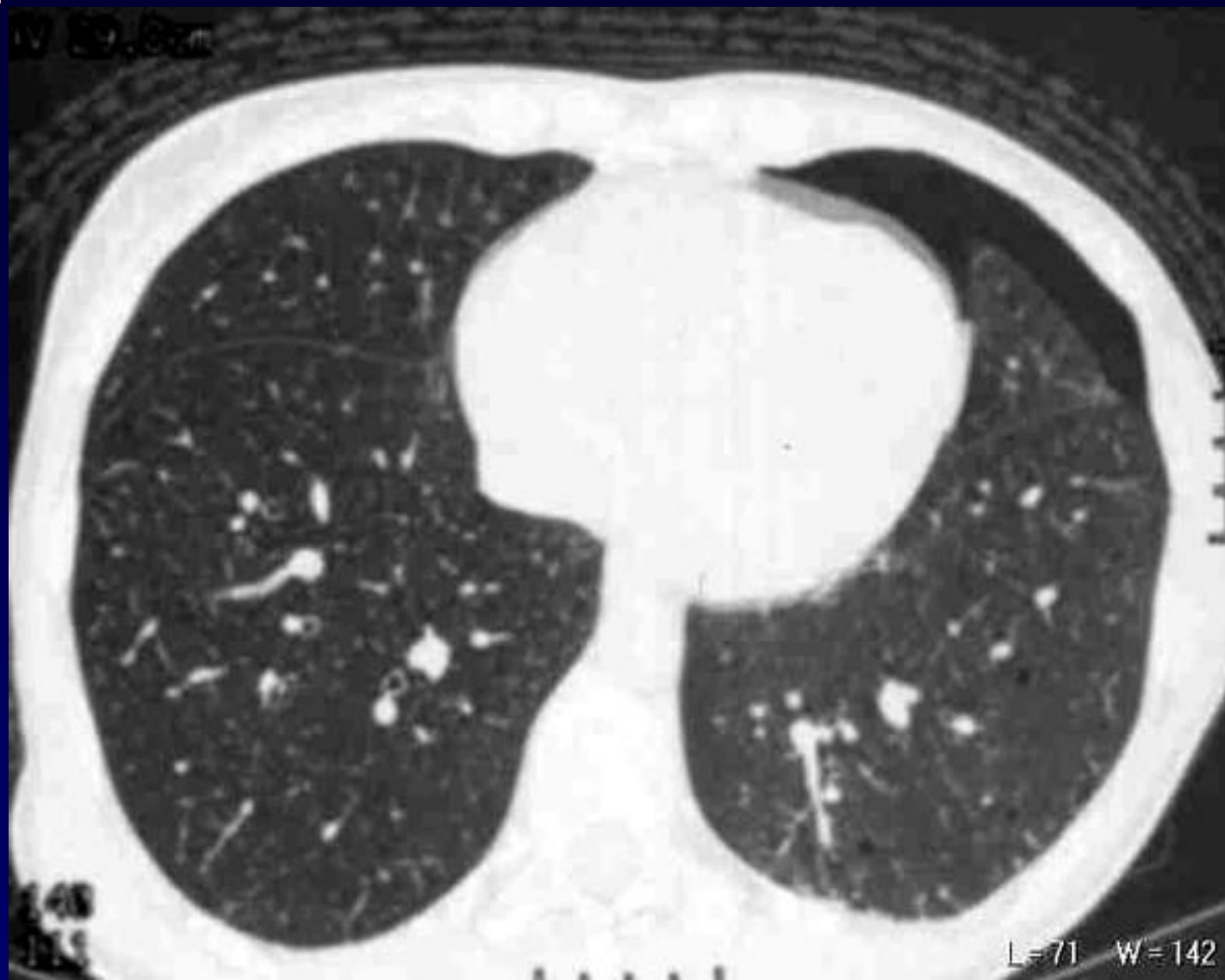
**J. GIRON**

**Femme de 34 ans**

**Douleur thoracique gauche**

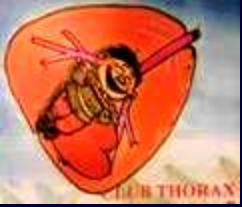







**Diagnostic ?**



**Association de lésions kystiques  
parenchymateuses bilatérales  
avec un pneumothorax**

**Lymphangiomyomatose**